

Paediatric lung isolation

M Letal MD FRGPC^{1,*} and M Theam MD FRGPC²

¹Paediatric Anesthesiologist, Department of Pediatric Anesthesia and Pain Medicine, Alberta Children's Hospital, 2888 Shaganappi Tr NW, Calgary, AB, Canada T3B 6A8 and ²Paediatric Anesthesia Fellow, Alberta Children's Hospital, 2888 Shaganappi Tr NW, Calgary, AB, Canada T3B 6A8

*To whom correspondence should be addressed. Tel: +1 403 955 7810; Fax: +1 403 955 7606; E-mail: michael.letal@albertahealthservices.ca

Key points

- When compared with adult anaesthesia, paediatric thoracic anaesthesia can be more difficult due to the wide variety of pathology and the size limitations of available lung isolation devices.
- Lung isolation is not always necessary for paediatric thoracic surgery. Many surgeries can be performed with conventional tracheal intubation.
- Unless contraindicated, the preferred lung isolation device for patients over 8 yr of age is the double-lumen tracheal tube.
- Under the age of 8 requires the use of a bronchial blocker or endobronchial intubation for lung isolation.
- All paediatric bronchial blockers should be considered to have high-pressure balloon cuffs. Due care is required during placement and inflation.

Lung isolation is required for a wide variety of pathology in paediatric patients. The varying size of the paediatric airway and size limitations of each lung isolation device poses a challenge to paediatric anaesthesiologists.

Indications for one-lung ventilation

The need for lung isolation includes: the prevention of contamination of one lung from the other due to haemorrhage or infection, the need to control the distribution of ventilation secondary to a bronchopulmonary fistula, a lung cyst or bullae, or severe hypoxaemia from unilateral lung disease. Extensive bronchopulmonary lavage may also necessitate lung isolation. Although lung isolation

can assist in surgical exposure, in the paediatric population, surgical exposure for lung resections, mediastinal exposure, and thoracoscopy can often be accomplished by the CO₂ pneumothorax and retraction of the operative lung without the need for lung isolation. This is most common in the young patient (<2 yr of age).

ABCDs of paediatric lung isolation

Slinger¹ teaches that there are the 'ABCs' of adult lung isolation: anatomy, bronchoscopy, and chest imaging. In paediatric lung isolation, there are still all the same 'ABC' considerations, with the addition of 'D'—the varying diameter of the paediatric airway with age.

Anatomy

It has been long established that there are differences between the paediatric and adult airway that are well known to the anaesthesiologist. Of all the airway differences, it is the smaller size of the paediatric airway that necessitates the need for a range of airway devices to provide one-lung ventilation. The preferred method of lung isolation in the adult population, a double-lumen tube (DLT), cannot be used in infants and small children because of the smaller airway size.

The anaesthesiologist must have proficient knowledge of tracheobronchial anatomy in order to optimally place lung isolation devices and troubleshoot problems using fiberoptic bronchoscopy.

Bronchoscopy

When choosing a bronchoscope to be placed within a tracheal tube (TT), there are two questions to ask: (i) What size bronchoscope can I use that will physically fit; (ii) What size bronchoscope can I use and still ventilate the patient?

What size bronchoscope can I use that will physically fit?

Bronchoscopes come in varying sizes. Bronchoscopes are labelled by the outside diameter (OD) of the scope.

The sizing of various types of TTs is done differently depending on type. A single-lumen tracheal tube (SLT) is labelled by the inside diameter (ID) of the respiration lumen. A double-lumen TT is labelled by the OD of the entire tube, with the measurement reported in French (Fr). Even though the OD is standardized, the ID of the double-lumen TT can vary between manufacturers. There is no need to memorize sizing tables, as one can obtain the ID of a lumen of any TT by simply looking on the package or in the package insert.

In order for a well-lubricated bronchoscope to physically fit inside the lumen of the TT (and not seize up from friction), the OD of the bronchoscope (OD_B) needs to be <90% of the ID of the TT (ID_{TT}). This can be written as $OD_B/ID_{TT} < 0.9$ (Fig. 1A).

What size bronchoscope can I use and still ventilate the patient?

In order to allow some ventilation during the time of bronchoscopy, the cross-sectional area of the bronchoscope (CSA_B) cannot take up more than 50% of the cross-sectional area of the TT lumen (CSA_{TT}). This can be written as $CSA_B/CSA_{TT} < 0.5$. For a circle inside a circle set-up (like a bronchoscope inside a TT), the mathematics simplifies to $OD_B/ID_{TT} < 0.7$ (Fig. 1B).

The smallest fiberoptic scope in general use is the Olympus BF N20,² with an OD of 2.2 mm. Placing this scope through a 2.5 SLT gives an OD_B/ID_{TT} ratio of 2.2/2.5 or 0.88. Since this ratio is <0.9 but >0.7, the bronchoscope will physically fit inside the TT, but no ventilation will be able to occur.

Care must be taken during the selection and use of a bronchoscope. Bronchoscopes can become deformed from repeated use and cleaning, and the tip may have a larger diameter than documented. It is always a good idea to test the fit of the bronchoscope inside a TT before use in the patient. During bronchoscopy, even if the CSA ratio is <50%, there will be an increase in airway resistance and a decrease in ventilation. A sick patient can quickly decompensate during bronchoscopy due to inadequate ventilation.

Chest imaging

As part of the preoperative assessment of the patient, the anaesthesiologist should always look at all available chest imaging, X-ray, or computed tomography (CT). These may reveal issues with lung isolation such as a narrowed distal trachea, or a compressed bronchus.¹ CT scans can also be used to assist in choosing an appropriate TT size. Ultrasound measurements of the upper trachea has been shown to correlate with left-bronchus sizing³ and potentially used to predict paediatric TT sizing.⁴

Diameter of the paediatric airway

The average neonatal trachea has an anteroposterior diameter of about 4.3 mm for both males and females.⁵ The trachea grows uniformly in males and females to about 14 mm at the age of 15 yr old. At this time, the female trachea stops growing.

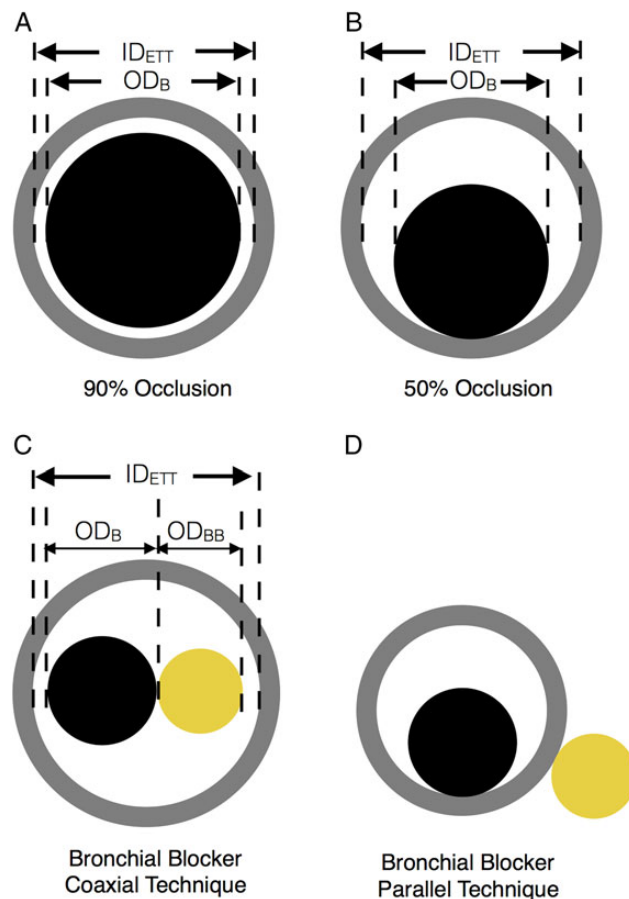


Fig 1 (A) Bronchoscopy tight fit, $OD_B/ID_{TT} < 0.9$. (B) To allow for some ventilation, $OD_B/ID_{TT} < 0.7$. (C) Bronchial blocker, coaxial technique, $(OD_B + OD_{BB})/ID_{TT} < 0.9$ to fit. (D) Bronchial blocker, parallel technique—the bronchial blocker is placed outside of the TT lumen. Grey circle represents the cross-section of TT, black circle represents the cross-section of bronchoscope, and yellow circle represents the cross-section of bronchial blocker.

However, the male trachea continues to grow to 16–18 mm by the age of 19. The trachea is the shape of an ellipse, with the transverse diameter being larger than the anteroposterior diameter.⁶ Sizing of airway devices should be based on the smaller (anteroposterior) diameter. Left and right mainstem bronchi diameters can be estimated, respectively, by using 0.66 or 0.86 fractions of the tracheal diameter⁷ (Table 1).

Options for lung isolation

Single-lumen tracheal tube

Preferred method for ages: 0–6 months

Acceptable method for ages: 0–18 yr

The simplest option for lung isolation is to place an SLT into the desired bronchus. This technique can be used at any age and is the most common option for the very young patient. Placement of an SLT in the right mainstem bronchus is easier than the left due to the less acute angle that it takes off from the trachea. Flexible fiberoptic bronchoscopy will greatly aid in tube placement.

Mainstem intubation with an SLT has the advantage of being simple and quick. Disadvantages of using an SLT for lung isolation include potential for inadequate collapse of the operative lung, inability to suction the operative lung, and inability to deliver continuous positive airway pressure (CPAP) to the operative lung. Given the short distance between the right mainstem bronchus and right upper lobe bronchus, ventilation may be limited in the right upper lobe when the right mainstem bronchus is intubated.

Alternatively, two SLTs may be placed in parallel,⁸ one into a mainstem bronchus, and the other into the trachea to allow independent lung ventilation. This technique is limited in the paediatric population, given their smaller anatomy size in relation to TT size.

Bronchial blockers

Preferred method for ages: 2–8 yr (coaxial technique)

Preferred method for ages: 6 months–2 yr (parallel technique)

Acceptable method for ages: 6 months–18 yr

Bronchial blockers include the vascular balloon catheters (Edwards Lifesciences, Irvine, CA, USA), the Uniblocker (Fuji Systems), and the Arndt endobronchial blocker (Cook Critical Care, Bloomington, IN, USA).

Vascular balloon catheters in the airway

Vascular balloon catheters, such as the Fogarty arterial embolectomy catheter, and Miller atrioseptostomy catheter (Edwards Lifesciences) have been successfully used for lung isolation.⁹

The more commonly used Fogarty catheters come in a variety of sizes. All but the smallest 2 and 3 Fr catheters have a removable guide wire that allow the user to angle the tip and direct the catheter into the desired bronchus to be isolated. The catheters may be placed either within or external to the TT. Positioning of the catheter is facilitated with a fiberoptic bronchoscope before balloon tip inflation. Because the Fogarty catheter has a low-volume, high-pressure balloon, it is imperative that a fiberoptic bronchoscope is used to observe the position and inflation of the balloon catheter to avoid damaging bronchial mucosa.¹⁰ Once inflated, the catheter must be secured against the lumen of the TT with an adapter. There is no central channel for deflation or CPAP to the operative lung. Deflation of the operative lung occurs by absorption atelectasis, and requires a considerably longer period of time.

Table 1 Types of airway devices that can be used vs patient age. Highlighted boxes are the authors' preferred airway device at the given age. Trachea size and device size selection are for the average patient of that age. Individual patient factors may warrant a different size device or different device selection

Age (yr)	Average patient airway diameter ^{5,6} (mm)			Double lumen		Univent		Bronchial blocker with SLT			SLT (OD may vary by manufacture)	
	Trachea		Bronchial (calculated as a percent of AP tracheal size) ⁷	OD (Fr)	OD (mm)	ID (mm)	OD Transv. (mm)	Size of bronchial blocker (Fr)	Size (mm)	Technique	ID (mm)	OD (mm)
	AP	Transverse										
18–20 male	17.5	16.6	11.6	41	13.7	8	13	7/9	2.3/3.0	Coaxial	8	10.8
16–18 male	15.7	15.9	10.4	39	13	7.5	12.5	7/9	2.3/3.0	Coaxial	7.5	10.2
14–16 male	14.5	14.3	9.6	37	12.3	7	12	7/9	2.3/3.0	Coaxial	7	9.6
18–20 female	14.2	13.9	9.4	37	12.3	7	12	7/9	2.3/3.0	Coaxial	7	9.6
16–18 female	13.7	14.0	9.0	37	12.3	7	12	7/9	2.3/3.0	Coaxial	7	9.6
14–16 female	13.9	14.6	9.2	35	11.7	6.5	11.5	7/9	2.3/3.0	Coaxial	7	9.6
12–14	13.0	13.3	8.6	32	10.7	6	11	7	2.3	Coaxial	7	9.6
10–12	11.6	11.8	7.7	28	9.3	4.5	9	7	2.3	Coaxial	6.5	8.9
8–10	10.5	10.7	6.9	26	8.7	3.5	8	7	2.3	Coaxial	6	8.2
6–8	9.2	9.3	6.1			3.5	8	5	1.7	Coaxial	5.5	7.5
4–6	8.0	9.0	5.3					5	1.7	Coaxial	5	6.8
2–4	7.4	8.1	4.9					5	1.7	Coaxial	4.5	6.2
0.5–2	5.3	6.4	3.5					5	1.7	Coaxial	4	5.5
0–0.5	4.3	4.7	2.8					5	1.7	Parallel	3.5	4.9

Another vascular device is the 5 Fr Miller Atrioseptostomy Catheter. It has an angled tip which allows the user to direct the catheter to the desired bronchus. It also has a high-pressure balloon and no central channel.

Uniblocker tube (Fuji Systems)

The 5 Fr Fuji Systems Uniblocker Tube is a relatively new bronchial blocker that has a stiff shaft and angled tip for positioning. It comes in a paediatric size of 5 Fr which is suitable for children up to 8 yr of age. It comes with a swivel connector so that one may ventilate the patient during placement. The balloon cuff is a maximum 3 ml and lower pressure system which theoretically decreases risk of bronchial mucosal injury. There is no central lumen for CPAP or suctioning.

Arndt blockers

The 5 Fr Arndt paediatric bronchial blocker is a catheter with a balloon tip and a four-way adapter. It also comes with a swivel connector. The blocker has a 2 ml cuff and lower inflation pressures. The Arndt blocker has an inner lumen that contains a flexible nylon wire that extends along the length of the catheter and terminates as a flexible loop. This loop slides over the bronchoscope and aids in positioning. It is important to note that once the nylon guide is removed, it cannot be reattached, which may make repositioning attempts difficult should the blocker fall out of place. Once the nylon wire is removed, the central lumen may be used for suctioning and CPAP.

Cuff pressures for bronchial blockers

Fogarty and atrial septostomy catheters are vascular devices used in an off-label indication when used as a bronchial blocker. These two vascular devices are often referred to as having high-pressure balloons.¹¹ When we tested the cuff pressure with the Fluke DPM4 Parameter Tester (Fluke Biomedical, Norway), the inflation pressures of these 5 Fr vascular devices with 2 ml of air were 710 and 690 cm H₂O, respectively.

The dedicated bronchial blockers are often referred to as lower pressure devices. Even the 5 Fr Arndt bronchial blocker has been said to have a 'high-volume, low-pressure balloon'.¹² When testing the 5 Fr Arndt bronchial blocker and the 5 Fr Fuji Uniblocker, we found inflation pressures with 2 ml of air to be 340 and 330 cm H₂O, respectively.

Whenever possible, a lower pressure bronchial blocker designed for the airway should be used preferentially over the higher pressure vascular devices in order to minimize bronchial trauma. However, since the inflation pressure of all bronchial blockers is greater than systolic arterial pressures, fiberoptic bronchoscopy should be used to ensure inflation volumes are kept to the minimal amount required to make a seal.

Sizing of bronchial blockers and bronchoscopes for SLTs

The same sizing principles apply when using bronchial blockers and bronchoscopes together as to when sizing bronchoscopes alone. Following a few simple principles will remove the need for sizing tables.

Typically in paediatrics, two sizes of bronchial blockers are used—5 and 7 Fr. Calculating the OD in millimetres is done simply by dividing the size in French by 3. Therefore, the 5 and 7 Fr bronchial blockers have ODs of 1.67 and 2.33 mm, respectively.

In order for a bronchial blocker and bronchoscope to physically fit together inside the lumen of the TT (coaxial technique), the

OD of the bronchial blocker (OD_{BB}) and the OD of the bronchoscope (OD_B) added together needs to be <90% of the ID of the TT. This can be written as $(OD_{BB} + OD_B) / ID_{TT} < 0.9$ (Fig. 1c).

In order to allow some ventilation during the time of bronchoscopy, the cross-sectional area of the lumen of the TT cannot be more than 50% blocked. Since there are two circular devices in the TT lumen (as opposed to just one for bronchoscopy alone), there should not be a scenario where the lumen of the TT is more than 50% blocked with the available sizes of bronchial blockers and bronchoscopes. Therefore, some ventilation should always be possible when both the bronchial blocker and bronchoscope are inside the TT lumen. Care must be taken with sick patients as they will decompensate quicker from the increased airway resistance and decreased ventilation.

Using the smallest fiberoptic scope with an OD of 2.2 mm and the smallest bronchial blocker (5 Fr) with an OD of 1.67 mm and the coaxial technique, the smallest SLT that can be used is a 4.5. This will have an additive diameter ratio of 0.86. This would correspond to a patient as young as 2 yr old.

For a patient under 2 yr of age, a bronchial blocker may still be used, but will need to be done by placing the bronchial blocker outside the TT lumen, or in parallel, with the bronchoscope remaining inside the lumen (Fig. 1d). This is done by first placing the bronchial blocker through the glottis and into the trachea and then intubating alongside with an SLT. A patient between the age of 6 months and 2 yr generally will tolerate a 3.5 or 4.0 TT with a 5 Fr bronchial blocker outside the TT. A microcuff TT may be chosen in order to decrease an air leak. The narrowest part of the paediatric airway is at the level of the cricoid, with the transverse diameter being larger than the anteroposterior diameter. It is this extra space laterally, in the elliptical shaped trachea, that allows the bronchial blocker to fit alongside the TT (Fig. 2).

When using the coaxial technique, the Arndt bronchial blocker works well. However, when using the parallel technique, a bronchial blocker with a stiffer shaft and angled tip should be used. This can be accomplished with the 5 Fr Fuji Uniblocker, or a vascular device such as a 5 Fr Fogarty embolectomy catheter, or a 5 Fr Miller atrioseptostomy catheter (Fig. 3).

Univent tube

Preferred method for ages: 6–8 yr

Acceptable method for ages: 6–18 yr

The Univent tube is a TT that has a bronchial blocker within a separate lumen. If double-lung ventilation is required again, the bronchial blocker may be deflated and withdrawn into the tracheal lumen again. Because the bronchial blocker balloon is at the distal end of the smaller lumen and affixed to it, there is less chance of dislodgement. Univent tubes are available in two paediatric sizes, 3.5 and 4.5 mm ID. In Univent tubes larger than 4.5 mm ID, there is an additional channel in the blocker that allows CPAP and suctioning of the operative lung. A fiberoptic bronchoscope should be used to position the bronchial blocker.

The main disadvantage of Univent tubes is that the cross-sectional diameter of the ventilation lumen is smaller in order to accommodate the blocker lumen. This increases airway resistance and also limits the size of fiberoptic bronchoscope used to facilitate positioning. It is important to remember that the size of a Univent TT refers to the ID, where the OD will be much larger than the equivalent sized SLT.

There is only a narrow age range where the Univent tube is the preferred method for paediatric lung isolation. The Univent TT is

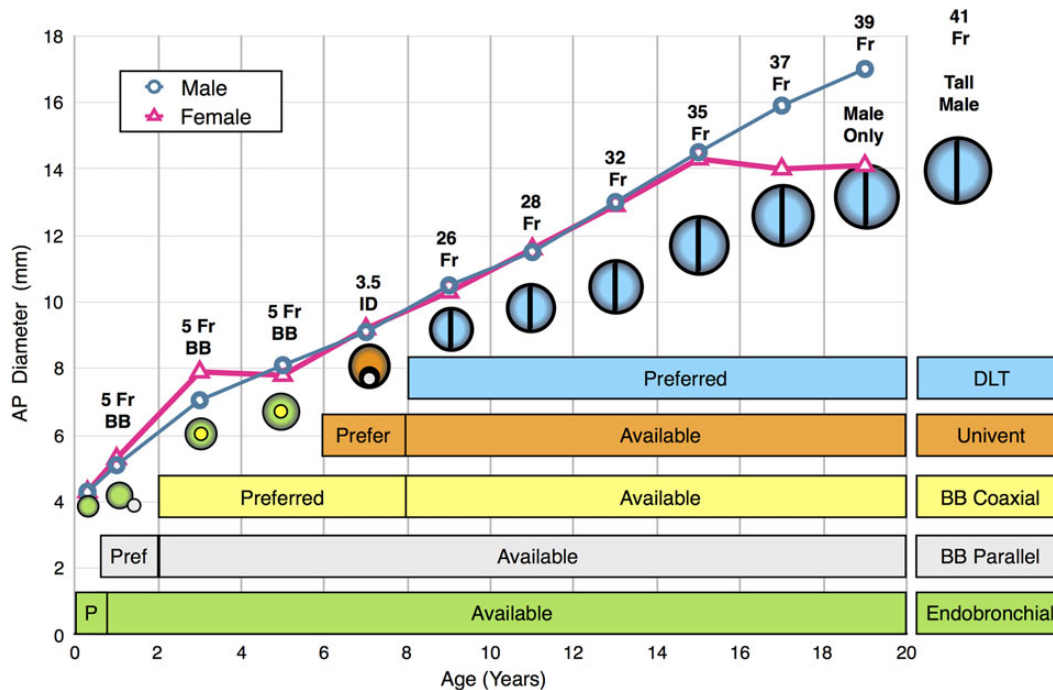


Fig 2 Anteroposterior trachea diameter vs age for male and female paediatric patients. Trachea diameters are from cadaveric⁵ and radiologic⁶ studies. Male and female airway sizes are similar until 15 yr of age, when the female trachea stops growing, but the male trachea continues to grow. Superimposed is the preferred airway device for lung isolation for a given age, placed on the graph at the given diameter of the device. Note that in order to use an airway device for a certain age, the diameter of that device must be smaller than the trachea AP diameter at that age. DLT, double-lumen tracheal tube; Univent, Fuji Univent tracheal tube; BB coaxial, bronchial blocker coaxial technique; BB parallel, bronchial blocker parallel technique; Endobronchial, endobronchial intubation with an SLT.

not suitable under the age of 6, whereas DLT is the preferred method for patients older than 8 yr. Given the narrow age range and the fact that there are other good tools available for this age range, some paediatric anaesthesiologists may wish to omit this tool from their armamentarium.

Double-lumen tube

Preferred method for ages: 8–18 yr

Acceptable method for ages: 8–18 yr

Often considered the gold standard for lung isolation, the double-lumen endobronchial blocker or DLT is suitable for children older than 8 yr of age (Table 1). The DLT is composed of two lumens fused in parallel with one lumen that is angled and longer than the other and meant to be inserted into the desired bronchus, while the shorter lumen remains in the trachea. Both lumens are cuffed such that single-lung ventilation and double-lung ventilation may be easily achieved by clamping and releasing the appropriate limb on the adapter piece.

The equation of $\text{Size} = \text{Age} \times 1.5 + 14$ can help to estimate the sizing needed. The smallest DLT size is a 26 Fr, which is generally suitable for children 8–10 yr of age. One study suggested that the use of the 26 Fr DLT may be considered for children as young as 8 yr and as small as 30 kg of weight and 130 cm of height. They should meet at least two of these parameters.¹³ After age 16, male and female tracheal diameters vary, with females averaging approximately between 14 and 16 mm in diameter, and males between 16 and 18 mm in diameter (Table 1). As children approach adulthood, it is thought that tracheal diameter is also related to patient height, and sizing for DLTs may be made based on sex and height. Slinger¹ advises that in the fully grown patient, females whose height is <1.6 m, a 35 Fr DLT may be used, whereas females whose height is >1.6 m are better

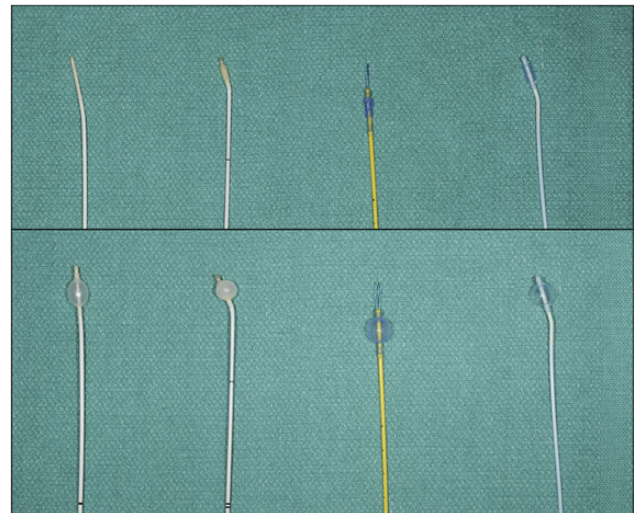


Fig 3 Photo of the different types of 5 Fr bronchial blockers deflated (above) and inflated (below) with 2 ml of air—balloon inflation pressures (cm H₂O). From left to right: Folgary embolectomy catheter (710), Miller atrial septostomy catheter (690), Arndt bronchial blocker (340), Fuji Unblocker (330).

sized with a 37 Fr DLT. A fully grown male whose height is <1.7 m should receive a 39 Fr DLT, whereas males whose height is >1.7 m should have a 41 Fr DLT.

DLTs are available in left- or right-sided tubes, although the left-sided tube is more commonly used as it avoids potentially obstructing the right upper-lobe bronchus. Insertion is performed by direct laryngoscopy, or in the case of a difficult airway, a fiberoptic scope or tube exchanger may be used. Once the bronchial tip is past the vocal cords, the preformed stylet is removed

and the tube rotated 90° towards the desired bronchus. The adapter piece is then connected, and tracheal cuff inflated and connected to the ventilator. Fiberoptic bronchoscopy is recommended to confirm placement. When inflated, the bronchial cuff should still be seen within the bronchus, but the majority of the cuff should be within the bronchus to avoid dislodgement during surgery. If a bronchoscope is unavailable, placement may be confirmed by auscultation of the lungs after occlusion of ventilation to the desired lung and verifying the absence of breath sounds.

Advantages of a DLT include the ability to quickly alternate from single-lung ventilation to double-lung ventilation, ease of insertion, application of CPAP, and suctioning of the operative lung. The most obvious disadvantage of the DLT in the paediatric population is its size limitation. Because of its configuration and larger diameter, the DLT is more challenging for patients with difficult airways. When lung isolation is not needed, the bronchial cuff should be deflated to decrease the risk of mucosal injury. If postoperative intubation and ventilation are required, the DLT should be replaced with an SLT to avoid unnecessary trauma to the tracheal-bronchial tree.

Declaration of interest

None declared.

MCQs

The associated MCQs (to support CME/CPD activity) can be accessed at <https://access.oxfordjournals.org> by subscribers to *BJA Education*.

References

1. Slinger P, ed. *Principles and Practice of Anesthesia for Thoracic Surgery*. Calgary, Canada: Springer, 2011
2. Roberts S, Thornington RE. Paediatric bronchoscopy. *Contin Educ Anaesth Crit Care Pain* 2005; **5**: 41–4
3. Sustic A, Miletic D, Protic A, Ivancic A, Cicvaric T. Can ultrasound be useful for predicting the size of a left double-lumen bronchial tube? tracheal width as measured by ultrasonography versus computed tomography. *J Clin Anesth* 2008; **20**: 247–52
4. Shibasaki M, Nakajima Y, Ishii S, Shimizu F, Shime N, Sessler DI. Prediction of pediatric endotracheal tube size by ultrasonography. *Anesthesiology* 2010; **113**: 819–24
5. Butz RO Jr. Length and cross-section growth patterns in the human trachea. *Pediatrics* 1968; **42**: 336–41
6. Griscom NT, Wohl ME. Dimensions of the growing trachea related to age and gender. *Am J Roentgenol* 1986; **146**: 233–7
7. Hammer GB, Fitzmaurice BG, Brodsky JB. Methods for single-lung ventilation in pediatric patients. *Anesth Analg* 1999; **89**: 1426–9
8. Paquet C, Karsli C. Technique of lung isolation for whole lung lavage in a child with pulmonary alveolar proteinosis. *Anesthesiology* 2009; **110**: 190–2
9. Golianu B, Hammer GB. Pediatric thoracic anesthesia. *Curr Opin Anaesthesiol* 2005; **18**: 5–11
10. Borchardt RA, LaQuaglia MP, McDowall RH, Wilson RS. Bronchial injury during lung isolation in a pediatric patient. *Anesth Analg* 1998; **87**: 324–5
11. Campos JH. An update on bronchial blockers during lung separation techniques in adults. *Anesth Analg* 2003; **97**: 1266–74
12. Wald SH, Mahajan A, Kaplan MB, Atkinson JB. Experience with the Arndt paediatric bronchial blocker. *Br J Anaesth* 2005; **94**: 92–4
13. Seefelder C. Use of the 26-French double-lumen tube for lung isolation in children. *J Cardiothorac Vasc Anesth* 2014; **28**: e19–21